

# ActiveVessel: A New Multimedia Workstation for Intravascular Ultrasound and Angiography Fusion

D Rotger<sup>1</sup>, M Rosales<sup>1,3</sup>, J Garcia<sup>1</sup>, O Pujol<sup>1</sup>, J Mauri<sup>2</sup>, P Radeva<sup>1</sup>

<sup>1</sup>Computer Vision Center, University Autònoma de Barcelona, Spain

<sup>2</sup>Hemodynamics, University Hospital Germans Trias i Pujol, Spain

<sup>3</sup>Laboratorio de Física Aplicada, University of Los Andes, Mérida, Venezuela

## Abstract

*ActiveVessel is a new multimedia workstation which enables the visualization, acquisition and handling of both image modalities, on- and offline. It enables DICOM v3.0 decompression and browsing, video acquisition, reproduction and storage for IntraVascular UltraSound (IVUS) and angiograms with their corresponding ECG, automatic catheter segmentation in angiography images (using fast marching algorithm), BSpline models definition for vessel layers on IVUS images sequence and an extensively validated tool to fuse information. This approach defines the correspondence of every IVUS image with its correspondent point in the angiograms and vice versa. The 3D reconstruction of the IVUS catheter/vessel enables real distance measurements as well as three-dimensional visualization showing vessel tortuosity in the space.*

## 1. Introduction

In many clinical scenarios, images from several modalities may be acquired and the diagnostic task is to mentally combine or fuse this information to draw useful clinical conclusions. In particular, in cardiology physicians work on different image modalities none of which contains the complete information about the vascular disease. [1]

Our first objective was to develop a new tool to easier the arduous task of conceptualization and mental combination of all this data coming from different instruments. Further, in many instances, this fusion process makes emerge new information that would not been easily deduced from each image or signal modality by itself.

In particular, our aim was to create a new application to fuse the information coming from the angiographic and the intravascular ultrasound equipments. But this first goal has lead us to the creation of ActiveVessel workstation which incorporates multimedia capabilities as video and audio acquisition, reproduction and storage for angiograms and IVUS images with their corresponding ECG signal.

It also handles relevant information about the patient and the study. A DICOM v3.0 decompressor and browser has also been implemented to manage angiographic data. An automatic segmentation method for the catheter present in the angiographic images, three-dimensional visualization of the vessel layers (extracted from the IVUS information) in the space (incorporating tortuosity coming from the angiographies) in OpenGL and some relevant measurements as real 3D distance between two certain points in the vessel or refereing to a bifurcation, area between vessel layers and exact correspondence between IVUS (in long- and short-axis view) and angiographies are some other relevant capabilities of our application.

## 2. ActiveVessel

As we mention in the introduction, the application has a wide range of capabilities so we will explain them in more detail chronologically from the moment the physician turns it on.

As soon as the application starts up the physician decides if he/she wants to start working online or offline.

In the online process, the first thing needed is the information about the study and the patient which is asked by means of a form. As we will see, in the case of offline process this information is extracted automatically from the data contained in the DICOM.

After this set up process, a set of images is needed. To reconstruct the IVUS catheter path from the angiographies we use the Dumay's method [2] with the (un)distortion corrections proposed at [3], so we need two pairs of angiographic series at the pullback beginning and another pair of them at the end.

In [4] we presented an acquisition protocol to assure the minimal error possible in the reconstruction of the path covered by the IVUS catheter during its pullback along the vessel. It consists of five steps:

a) Choose two optimal views (minimum foreshortening) of the catheter with an angulation between both projections greater than or equal to 30 degrees [2], avoiding to change the distance between the intensifier and the isocenter (OC).

- b) Acquire the first projection with the catheter stopped at the beginning of the pullback, asking the patient to keep the breathing to avoid displacement during the sequence.
- c) Acquire the second projection without changing the OC and avoiding to use saved positioning (great mechanical error).
- d) Do the pullback of the IVUS catheter without moving the C-Arm.
- e) Acquire two more projections with the catheter stopped and the pullback's end following steps 3 and 2.

To avoid being so restrictive in the acquisition process, currently we are working on including a precise intensifier location that will permit the physician to change the OC distance between both projections and also to track the catheter position during the positioning of the intensifier, accelerating the acquisition and the catheter detection.

### 2.1. Video and ECG recorder

To perform this acquisition protocol the workstation has been gifted with a real-time video and ECG acquisition module consisting in an Euresys video capture card and a SoundMax sound card. A video output of the angiographic equipment, containing the same information shown in the laboratory monitors, is used as an input for the system. A region of interest (ROI) of 512x512 containing the angiography is defined on the input signal to accelerate the storage process. Figure 1(a) shows a screen shot of the recorder dialog.

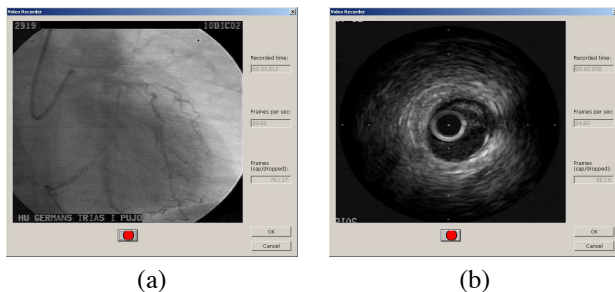


Figure 1. Screen shot of the angiography (a) and IVUS (b) recorder dialog.

For the ECG signal acquisition, we use the workstation sound card with a voltage and current attenuator to avoid over-saturation. Given that the sound card works as a band-pass filter, the input signal has to be integrated in a sliding window in order to recover its original shape. Figure 2 shows a recovered ECG.

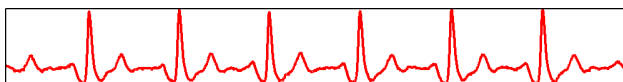


Figure 2. Recovered ECG from input signal.

Once we have the ECG recovered and the angiographic images recorded, we automatically select the angiographies corresponding to the end of the S curve of the ECG to assure maximum ventricular volume, as figure 3 shows [5].

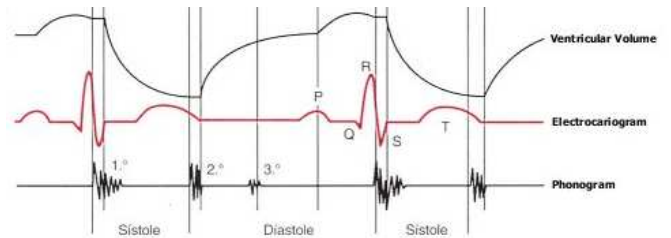


Figure 3. ECG and ventricular volume relationship (Reprint).

The same recording procedure is taken for IVUS data. In this case, the ROI selected is of 456x456 pixels and the frame rate is 25fr/sec. Figure 1(b) shows a screen shot of the recorder dialog.

### 2.2. Offline process

The application also incorporates a DICOM CD browser to permit the analysis offline for angiographic and IVUS data. This browser presents a list of all the studies contained in the CD and the user is able to select the one desired (figure 4).

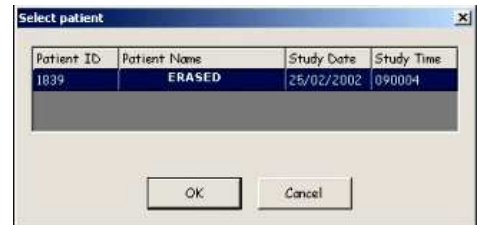


Figure 4. DICOM study selector.

Once the desired study is selected, a series browser is presented with relevant data about the study (see figure 5). Each series can be played with common video player options (see figure 6).

In the case of IVUS data the images can be easily loaded as a bitmap sequence, only providing to the system information about the used frame rate and the distance (in millimeters) between two consecutive grid marks in the IVUS image.

Whether the images have been acquired directly using the recorder module, or loaded directly as a bitmap sequence, a new module of the application permits to define closed models of the vessel layers as closed B-Splines (see figure 7).

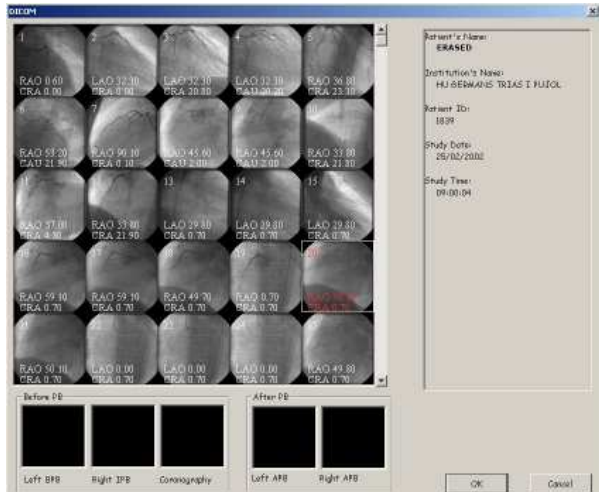


Figure 5. DICOM series browser.

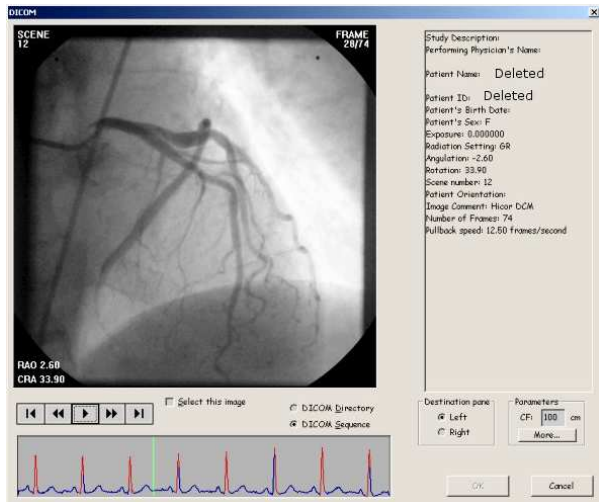


Figure 6. DICOM series player.

### 2.3. Fusion process

Given that X-Ray images are characterized with a low signal-to-noise rate, the fusion process has to begin with a local enhancement of the angiographic image to help in the catheter segmentation following the fast marching algorithm in a surface of minimal action (see [6]) computed in both angiographic projections of the IVUS catheter. The complete procedure of enhancement and segmentation is explained in [4].

The segmented catheter is placed in the space following the methodology proposed by Dumay et al. in [2] and the steps explained in [7]. This method consists in establishing a global reference system with its origin in the isocenter of both image projections. This global system permits establishing exact correspondence between

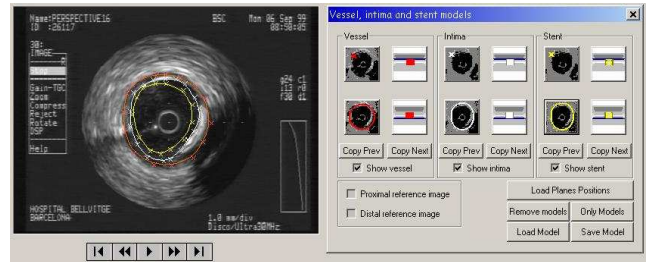


Figure 7. 2D models defined as closed B-Splines on the IVUS data.

the segmented catheter paths of both projections and, consequently, recover the real 3D path the catheter has followed during its pullback inside the blood vessel.

This image fusion leads us to the exact correspondence between IVUS and angiograms, what is the main module of the application, given that it implies a direct interaction between the physician and both image modalities at the same time.

This correspondence is established by measuring the reconstructed path length in 3D. Taking into account that we have the ECG not only for angiograms, but also for the IVUS cube of images, we can select the images corresponding to the same cardiac cycle in both image modalities to avoid imprecise calculus of the IVUS image position along the recovered path curve. This procedure can be seen as an ECG-gated acquisition, but instead of stopping the catheter pullback waiting for the next ECG pick, the application records all the pullback non-stop and permits viewing all the images of the pullback, determining its position depending on the cardiac cycle corresponding to them.

The application shows a dialog containing one of the angiographies of the studied vessel, the IVUS image corresponding to the point selected in the angiography and a long-axis view of the IVUS stack of images as figure 8 shows.

### 2.4. Three-dimensional visualization

The fusion of IVUS with angiographies combined with the two-dimensional models of the vessel layers defined on the IVUS images has permitted the visualization of this models with its tortuosity in 3D. The way of placing this models along the 3D curve corresponding to the IVUS pullback is by orienting the X- and Y-axis of the IVUS image with the normal and binormal of the curve, respectively [8]. This allows transforming the 2D curve models to a 3D Non-Rational B-Spline (NURB) surface in OpenGL (see figure 9).

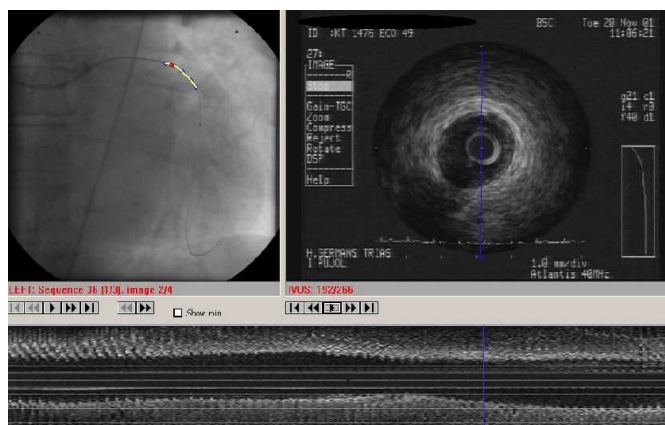

Figure 8. Registration of angiogram and IVUS data: the red point in the angiogram (top on the left) corresponds to IVUS short-axis view (top on the right) and to the blue line in the long-axis view of IVUS data (bottom)




Figure 9. Three-dimensional visualization on vessel layers.

### 3. Results

The presented workstation is being used by the physicians of University Hospital Germans Trias i Pujol, with very good acceptance. It helps them in the diagnosis and storage of all the data relevant to a study, speeding up the process of evaluation and treatment of coronary lesions.

The system is capable to record and handle more than 3000 IVUS images of 456x456 pixels with a frame rate of 25fps with their correspondent ECG data sampled at 10MHz (without loss) on an Intel Pentium III 866MHz dual processor with 512Mb of RAM with Microsoft Windows 2000 Professional and an Euresys Piccolo video capture card and an integrated SoundMax audio capture card (for ECG). That represents more than 6cm pullback at constant speed pullback of 0.5mm/sec.

### 4. Conclusions and future lines

To sum up, ActiveVessel represents a very useful tool for hospitals used to IVUS and angiography which permits on- and offline evaluation of stenosis, stent implantation and balloon treatments highly appreciated by our medical collaborators.

As future lines of work we can remark the previous topics: the angiographic system provides the position of the X-Ray intensifier with very low precision. One of our future lines is to develop a new precise positioning mechanism for the intensifier that will allow online movement of the C-Arm and making easier the acquisition protocol.

Tissue characterization is another problem to be studied. Combining the three-dimensional placement of the IVUS data with the tissue characterization will allow to generate automatic diagnostics of the vessel pathologies.

### References

- [1] Hajnal JV, Hill DLG, Hawkes DJ. Medical Image Registration. The Biomedical Engineering Series, 2001.
- [2] Dumay A, Reiber J, Gerbrands J. Determination of optimal angiographic viewing angles: Basis principles and evaluation study. *IEEE Medical Imaging* 1994;13:13–23.
- [3] Cañero C, Vilariño F, Mauri J, Radeva P. Predictive (un)distortion model and 3d reconstruction by biplane snakes. *IEEE Transactions on Medical Imaging* September 2002; 21(9).
- [4] Rotger D, Radeva P, Fernandez-Nofrerias E, Mauri J. Multimodal registration of intravascular ultrasound images and angiography. In *Proceedings of the XX Congreso Anual de la Sociedad Española de Ingeniería Biomedica (CASEIB)*. 2002; 137–140.
- [5] Guyton AC, Hall JE. *Tratado de fisiología médica (Textbook of Medical Physiology)*. McGraw-Hill/Interamericana de España, S.A.U., 2002. ISBN 84-486-0322-2.
- [6] Cohen L, Kimmel R. Global minimum for active contour models: A minimal path approach. In *IJCV*, volume 24(1). 1997; 57–78.
- [7] Rotger D, Radeva P, Mauri J. Internal and external coronary vessel images registration. *Congres Catala d Intel·ligència Artificial CCIA* 2002;.
- [8] Rotger D, Radeva P, Cañero C, Villanueva JJ, Mauri J, Fernandez-Nofrerias E, Tovar A, Valle V. Corresponding ivus and angiogram image data. *Proceedings of Computers in Cardiology* September 2001;28:273–276.

Address for correspondence:

David Rotger Muñoz  
 Centre de Visió per Computador  
 Edifici O, Campus UAB / 08193 Bellaterra (Cerdanyola)/ Spain  
 tel./fax: +34-93-581-18-28/16-70  
 rotger@cvc.uab.es